

Hepatoprotective action of *Pterocarpus marsupium* against streptozotocin-induced oxidative stress

Rajnish Gupta & R.S. Gupta*

Reproductive Physiology Section, Centre for Advanced Studies, Department of Zoology, University of Rajasthan, Jaipur, India 300204

Abstract

Pterocarpus marsupium Roxb. (Leguminosae) is widely used in Ayurvedic medicine as 'Rasayana' for management of various metabolic disorders including hepatotoxicity. Treatment of diabetic rats with methanol extracts of *P. marsupium* at 100 and 300 mg per kg-bwt per day for 21 days dose-dependently decreased serum glucose level. The higher dose exerted a protective effect on antagonized biochemical parameters such as reduced glutathione, superoxide dismutase and lipid peroxidation, and altered towards the normal levels hepatic mass, protein and glycogen content. In conclusion present results suggest antidiabetic, hepatoprotective as well as antioxidant effect of *P. marsupium*.

Keywords: antidiabetic, hepatotoxicity, lipid peroxidation, reduced glutathione, serum glucose, superoxide dismutase.

Introduction

Many traditional plants are used throughout the world for treating diabetes mellitus; plants used in folk medicine represent a viable alternative to modern drugs (Maroo *et al.* 2002), and are claimed to have few or no side effects. The minority of medicinal plant treatments for diabetes has received scientific scrutiny, for which the World Health Organization has also recommended attention (WHO 1993).

Pterocarpus marsupium Roxb. is a deciduous, commonly distributed tree in India, Nepal and Sri Lanka (Grover *et al.* 2001), and is valued for its pharmaceutical properties such as being an astringent used for the treatment of dysentery, diarrhoea, fever and toothache (Husain *et al.* 2007). It is also reported to be rich in polyphenolic compounds such as marsupsin, pterosupin and pterostilbene (Manickam *et al.* 1997: see Fig. 1) and the flavonoids pteroxide, pteroisouaroside, marsuposide, vijayoside, vijayosine etc. (Maurya *et al.* 2004). Separate studies of the antihyperglycemic (Vats *et al.* 2002) and antihepatotoxic (Mankani *et al.* 2005) activities of this plant have been reported previously, but proper scientific research to evaluate its integrative hepatoprotective activity in severe hyperglycemia is lacking. We therefore undertook the present study to evaluate the hepatoprotective efficacy of *P. marsupium* methanolic extract in streptozotocin-induced diabetic rats.

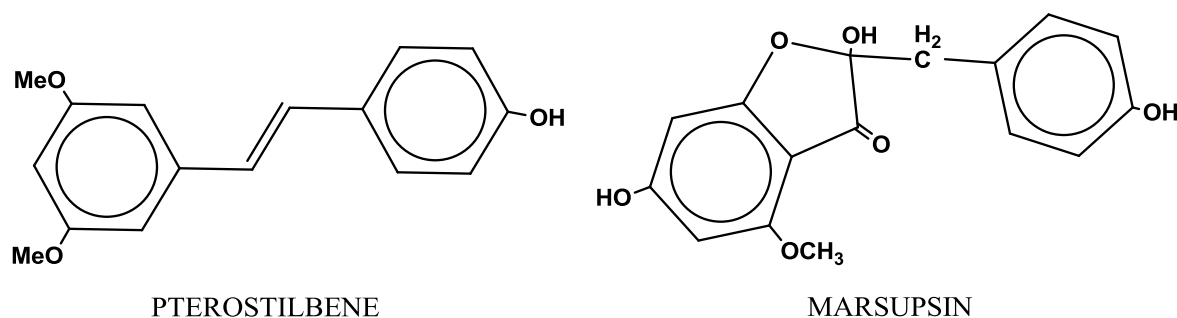


Figure 1: Structure of two polyphenols from *Pterocarpus marsupium*

* Author for correspondence: email : gupta_rs@hotmail.com

Materials & Methods

Colony bred, adult, male albino Wistar rats (180 ± 20 g) were housed in plastic cages and maintained under standard conditions of temperature (25 ± 3 °C), 12L:12D photoperiod and 35-60 % relative humidity. Animals had free access to food (commercial pelleted diet procured from Hindustan Levers Ltd., India) and drinking water. The study was approved by the Ethical Committee of the Centre for Advanced Studies, Department of Zoology, University of Rajasthan, Jaipur, India. The Indian National Science Academy (INSA), New Delhi Guidelines was followed for the maintenance and use of experimental animals.

Pterocarpus marsupium stem bark was purchased from local markets and authenticated by Dr. Mohan Shankar Dashora (Department of Dravya Guna, National Institute of Ayurveda, Jaipur, India). The stem bark was powdered, subjected to Soxhlet with methanol (100%) for 72 h and separated under reduced pressure to obtain a chocolate-brown viscous mass. This material was vacuum-evaporated to get a yield of 11.87% ^{w/w}.

Diabetes was induced in overnight-fasted rats by a single intraperitoneal injection during the morning hours of freshly prepared 0.2 ml solution of streptozotocin (Himedia Laboratory Ltd, Mumbai, India: 50 mg per kg body weight (kg-bwt) dissolved in 0.1 mM sodium citrate buffer): the pH was adjusted to 4.5. After 72 h of streptozotocin administration, the serum glucose was measured and animals were considered as diabetic when the observed glucose level was above 250 mg/dl. The control rats were injected with 0.1 mM sodium citrate buffer alone. Diabetic animals were allowed to drink 2% glucose solution overnight to overcome the drug-induced hypoglycemic shock.

Plant extract was reconstituted in distilled water and administered orally in the morning hours at fasting condition (once a day). Rats were randomized into five groups of 7 rats:

Group I: Negative control group for 21 days

Group II: Diabetic control group for 21 days

Group III: *Low* group (100 mg per kg-bwt per day of plant extract) for 21 days

Group IV: *High* group (300 mg per kg-bwt per day of plant extract) for 21 days

Group V: Positive control group (0.3 mg per kg-bwt per day of gibenclamide) for 21 days

Fasting serum glucose was measured by using a commercially available kit based on the glucose oxidase method (Trinder 1969) (Ecopak[®], Accurex Biomedical Pvt. Ltd., Mumbai).

At the end of experiment, animals were sacrificed using a mild ether anaesthesia. The liver was dissected out, washed in ice-cold saline (0.9%), blotted dry and weighed. Liver weight was expressed as 'relative liver weight', i.e. as a percentage of the total body weight. The liver was fixed in Bouin's fixative for histopathological studies, but a part was kept at 4°C for biochemical estimations: glycogen (Montgomery 1957), protein (Lowry *et al.* 1951), lipid peroxidase (LPO) (Ohkawa *et al.* 1979), superoxide dismutase (SOD) (Marklund & Marklund 1974) and reduced glutathione (GSH) (Moron *et al.* 1979). Blood was collected by cardiac puncture and the serum separated for biochemical estimations: serum aspartate transaminase (AST) and alanine transaminase (ALT), measured according to the method of Reitman & Frankel (1957). The serum total creatinine content was measured by the method of Varley (1969).

Values are given as mean \pm standard error of the mean, and compared using one-way ANOVA followed by the Tukey-Kramer multiple-comparison test to assess where the differences lie among the various groups. Student's "t-test" was also used to determine which mean was statistically significant. Values of $p < 0.05$ were considered statistically significant.

Results

In diabetic rats, the liver weight markedly decreased and the serum glucose level increased significantly over normal controls. The low dose of plant extract caused a recovery of liver weight and reduced serum glucose level significantly; high doses and the positive control (glibenclamide) improved liver weight and markedly reduced serum glucose levels (Table 1).

Table 1: Effect of methanolic extract of *P. marsupium* at low or high doses on serum glucose and relative liver weight in streptozotocin-induced diabetic rats

Group	Serum glucose (mg/dl)		Relative liver wt (%)
	Initial	Final	
I. Normal Control (vehicle treated)	84.6 ± 11.6	85.3 ± 13.5	4.9 ± 0.1
II. Diabetic control	86.3 ± 12.5 ^{ns}	273.6 ± 3.2 ^{**}	4.1 ± 0.1 ^{**}
III. Diabetic + Low treatment	89.9 ± 12.6 ^{ns, ns}	228.3 ± 15.3 ^{*, ns}	4.3 ± 0.1 ^{*, ns}
IV. Diabetic + High treatment	85.4 ± 14.8 ^{ns, ns}	156.2 ± 16.2 ^{ns, a}	4.9 ± 0.1 ^{ns, a}
V. Positive control	83.8 ± 15.1 ^{ns, ns}	133.7 ± 14.8 ^{ns, a}	5.1 ± 0.2 ^{ns, a}
	F _{4,30} =0.825 ^{ns}	F _{4,30} =161.3 ^{**}	F _{4,30} =20.4 ^{**}

Values are given as mean ± sem (n = 7); the diabetic control (II) is compared with the normal control (I); experimental groups are compared first with normal (* = p < 0.05, ** = p ≤ 0.001) and then diabetic (a = p < 0.05, b = p ≤ 0.001) controls; ^{ns} = non-significant. F-tests provide the results of a one-way Anova testing for differences in the mean values among the five groups.

Glycogen and protein contents were decreased in diabetic rats as compared to controls (Table 2). Significant increases in hepatic glycogen and protein contents were mostly observed when low or high doses of plant extract were administered. Orally administered glibenclamide brought back glycogen and protein content nearer to normal.

Table 2: Effect of methanolic extract of *P. marsupium* at low or high doses on hepatic glycogen, protein content and three liver enzymes (lipid peroxidase LPO, reduced glutathione GSH, and superoxide dismutase SOD) in streptozotocin-induced diabetic rats. Abbreviations and details as in Table 1.

Group	Glycogen (mg/g)	Protein (mg/g)	LPO (n mole MDA/ mg protein)	GSH (n mole/g tissue)	SOD (μmole/mg protein)
I. Normal Control	5.8 ± 0.4	440.5 ± 11.2	2.4 ± 0.6	4.5 ± 0.2	11.7 ± 0.6
II. Diabetic control	3.1 ± 0.1 ^{**}	347.7 ± 9.5 ^{**}	8.6 ± 0.8 ^{**}	2.7 ± 0.2 ^{**}	6.2 ± 0.7 ^{**}
III. Diabetic + Low	3.6 ± 0.1 ^{*, a}	366.1 ± 7.7 ^{*, ns}	7.4 ± 0.5 ^{ns, ns}	3.1 ± 0.1 ^{*, ns}	6.4 ± 0.6 ^{*, ns}
IV. Diabetic + High	5.0 ± 0.04 ^{ns, b}	424.2 ± 5.3 ^{ns, b}	3.9 ± 0.04 ^{ns, b}	4.2 ± 0.1 ^{ns, ns}	7.7 ± 1.7 ^{ns, ns}
V. Positive control	5.4 ± 0.1 ^{ns, b}	437.7 ± 4.1 ^{ns, b}	3.1 ± 0.1 ^{ns, b}	4.5 ± 0.2 ^{ns, ns}	8.3 ± 1.5 ^{ns, ns}
	F _{4,30} =31.7 ^{**}	F _{4,30} =31.7 ^{**}	F _{4,30} =27.4 ^{**}	F _{4,30} =21.1 ^{**}	F _{4,30} =4.3 (p=0.05)

A significant elevation in liver LPO and reduction in GSH and SOD levels were observed in diabetic rats as compared with controls (Table 2). Oral administration of low doses of plant extract shows significant reduction in hepatic LPO, and increase in GSH and SOD. High doses

and the positive control caused slight decreases in liver LPO and increases in GSH and SOD levels.

Table 3 shows markedly increased serum AST, ALT and creatinine content in hyperglycemic rats after 21 days. Plant extract treatment at low doses significantly decreased some of these levels, while high doses and the positive control of glibenclamide led to levels no different from the normal controls.

Table 3: Effect of methanolic extract of *P. marsupium* at low or high doses on serum aspartate transaminase (AST), alanine transaminase (ALT) and creatinine levels in streptozotocin-induced diabetic rats. Abbreviations and details as in Table 1.

Group	AST (IU/L)	ALT (IU/L)	Creatinine (mg/dl)
I. Normal Control	11.0 ± 2.1	14.1 ± 0.8	0.8 ± 0.2
II. Diabetic control	28.8 ± 2.1**	24.4 ± 1.1**	2.4 ± 0.1**
III. Diabetic + Low	25.1 ± 1.4*,ns	21.4 ± 1.9*,ns	1.6 ± 0.1*,a
IV. Diabetic + High	14.5 ± 0.9 ^{ns,b}	15.8 ± 0.9 ^{ns,b}	1.1 ± 0.2 ^{ns,b}
V. Positive control	12.7 ± 0.8 ^{ns,b}	14.6 ± 0.8 ^{ns,b}	0.9 ± 0.2 ^{ns,b}
	F _{4,30} =22.7**	F _{4,30} =13.4**	F _{4,30} =12.3**

Histological examinations of liver sections from the five groups are shown in Figs 2-6. That of the negative control (Fig 2) shows normal histoarchitecture: the branches of the portal vein and hepatic artery, the biliary duct, the normal number of kupffer cells, normal sinusoids and prominent nuclei are clearly visible. Streptozotocin-induced diabetes caused distortion in the liver, with cytoplasmic vacuolization (Fig 3). Low doses of plant extract brought about moderately normal hepatocyte architecture, with almost intact cells and decreased cytoplasmic vacuolization (Fig 4). High doses showed almost normal liver histoarchitecture, with preserved cytoplasm, prominent nuclei and normalized sinusoidal spaces (Fig 5).

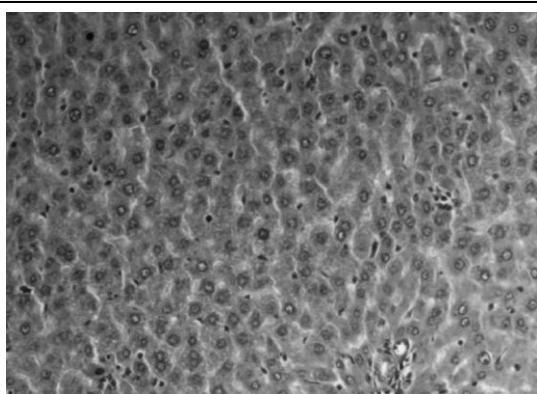


Figure 2: Photomicrograph of the liver section of a normal control rat, showing normal hepatic architecture

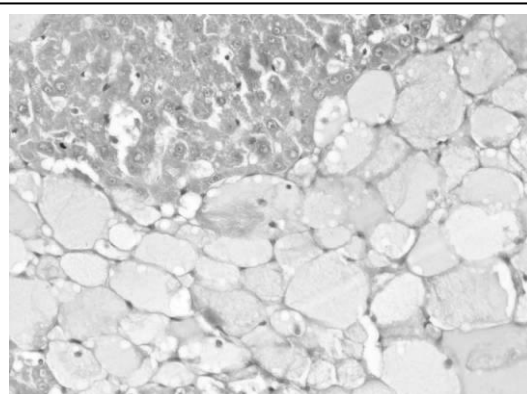


Figure 3: Photomicrograph of the liver section of a diabetic control rat, revealing distorted hepatic architecture

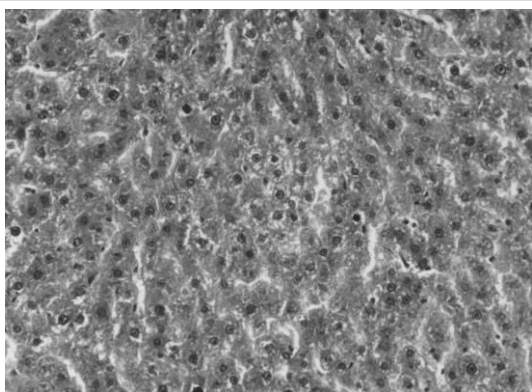


Figure 4: Photomicrograph of the liver section of a rat given the low dose of plant extract, showing moderately normal hepatocyte architecture

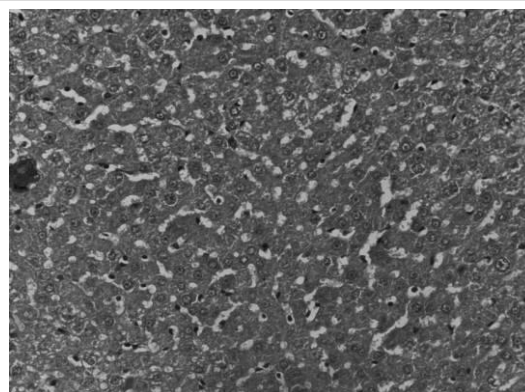


Figure 5: Photomicrograph of the liver section of a rat given the high dose of plant extract, showing moderately normal hepatocyte architecture

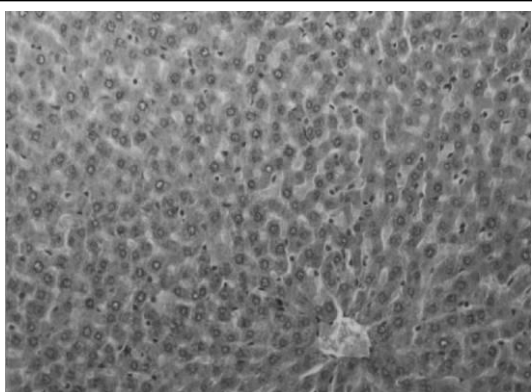


Figure 6: Photomicrograph of the liver section of a positive control (gibenclamide) rat, showing normal hepatic architecture

Discussion

Despite the great efforts that have been made in the understanding and management of diabetes, the disease and disease-related complications such as cardiomyopathy, diabetic neuropathy, nephropathy, diabetic retinopathy, thyroid disease and delivering a baby with macrosomia are increasing unabated. The liver is a versatile organ in the body concerned with the regulation of carbohydrate metabolism. Damage to the liver may cause, contribute to, be coincident with, or occur as a result of diabetes. Severe hyperglycemia may cause liver abnormalities such as steatosis, non-alcoholic steatohepatitis, fibrosis, cirrhosis, cholelithiasis, cholecystitis, hemochromatosis and autoimmune biliary diseases.

P. marsupium has been used for a long time by Indian traditional healers to treat diabetes, but there are not enough scientifically controlled studies that demonstrate its hepatoprotective activity in severe hyperglycemia. The plant methanolic extract is rich in polyphenolic compounds and flavonoids, and it is well known that two phenolic constituents (marsupsin, pterostilbene) and the flavonoid epicatechin have been shown to produce a significant hyperglycemic effect by enhancing insulin release and conversion of proinsulin to insulin (Manickam *et al.* 1997). According to the method the traditional healers suggest, a daily dose of the methanolic extract of *P. marsupium* was administered to diabetic rats. Our

results showed significant and sustained hypoglycemia as well as hepatoprotection after 21 days of daily administration.

Streptozotocin-induced diabetes in rats is associated with impaired hepatic metabolism (Cho *et al.* 2002). The results presented here demonstrate that rats made diabetic with streptozotocin have significantly lowered hepatic weight as well as increased concentrations of serum glucose. Plant-extract treatment of diabetogenic rats altered hepatic weight towards normal levels.

The hyperglycemic effect of streptozotocin is due to excess production of reactive oxygen species, leading to cytotoxicity in pancreatic β cells, which decrease the synthesis and release of insulin, and also affecting the liver (Sacan *et al.* 2006). Diminution in antioxidant enzyme levels and elevation in lipid peroxidation in streptozotocin-induced diabetes has also been noticed (Gupta *et al.* 2004). Continuous administration of *P. marsupium* extract at levels of 100 and 300 mg per kg-bwt per day to diabetic rats caused a decline in serum glucose levels in a concentration-dependent manner (Table 1). Our results also suggest that the higher dose restores antioxidant enzymes and decreases lipid peroxidation in diabetic animals (Table 2). Decreased liver antioxidant enzymes during diabetes may be a result of their increased utilization by hepatic cells, possibly reflecting an attempt to counteract increased formation of lipid peroxides: tissue damage caused by lipoxygenase-derived peroxides is closely related to insulin secretion. High doses reduced the formation of malondialdehyde (Table 2).

We have found that *P. marsupium* extract decreases streptozotocin-induced hyperglycemia serum glucose in streptozotocin-diabetic rats. The possible mechanism by which *P. marsupium* extract brings about its hyperglycemic action may be by potentiating the insulin effect by increasing either the pancreatic secretion of insulin from the β cells of the islets of Langerhans, or its release from bound insulin (Twaij & Al-Badr 1988).

Glycogen and protein metabolism are abnormal in diabetes due to insulin-secretion defects, leading to various metabolic disorders and complications (Goldstein *et al.* 2004). A significant fall in serum protein concentration was noticed in diabetic rats. *P. marsupium* extract treatment to diabetic rats elevated serum protein levels, which might be due to increased insulin synthesis, which promotes amino acid uptake, enhances protein synthesis and inhibits protein degradation (Rosen *et al.* 1981).

Streptozotocin-treated animals had significant hepatic damage, as shown by serum marker levels. The rise in the SGOT is usually accompanied by elevated SGPT level (Sallie *et al.* 1999). 21 days of plant extract treatment at both doses levels significantly attenuated the elevated serum marker levels. Serum marker normalization by *P. marsupium* extract suggests that it is able to condition the hepatocytes so as to protect membrane integrity against streptozotocin-induced leakage into the circulation. Serum creatinine levels are also raised when the hepatic biliary system is affected in diabetes (Hara 2003). As observed in our data *P. marsupium* extract possesses the capacity to reduce serum creatinine when orally administered, and improves serum creatinine levels in diabetic rats.

The histopathology of the liver showed that degeneration with distorted hepatic architecture in diabetic rats might be due to the streptozotocin-mediated increase in oxidative stress that produces peroxides, and results in changes in the function, structure and survival of liver cells. Diabetes-mediated free-radical production also triggers apoptosis in liver cells (West 2000). The oral administration of *P. marsupium* extract to diabetic rats caused normalized histoarchitecture with arranged hepatic plates, filled with dense cytoplasm and prominent nuclei; this may be due to the nurture and regeneration of the streptozotocin-damaged hepatic cells.

In conclusion, *P. marsupium* extracts exert antihyperglycemic as well as hepatoprotective efficacy against streptozotocin-induced diabetes. Future work with this plant will be to purify and characterize the active hepatoprotective constituents with the aim of diabetes therapy.

Acknowledgements

The investigation was financially supported by Department of Science & Technology, Jaipur, India (DST project: 1953/2007) and UGC regional office Bhopal (MP). The authors thank the Head and Coordinator CAS, Department of Zoology, University of Rajasthan, Jaipur (India) for providing necessary facilities.

References

- Cho SY, Park JY, Park EM, Choi MS, Lee MK, Jeon SM, Jang MK, Kim MJ & Park YB (2002) Alteration of hepatic antioxidant enzyme activities and lipid profile in streptozotocin-induced diabetic rats by supplementation of dandelion water extract. *Clinica Chimica Acta* 317: 109-117.
- Goldstein DE, Little RR, Lorenz RA, Malone JJ, Nathan D, Peterson CM & Sakcs DB (2004) Test of glycemia in diabetes. *Diabetes Care* 27: 1761-1773.
- Grover JK & Vats V (2001) Shifting the paradigm from conventional to alternative medicine: an introduction to traditional Indian medicine. *Asia Pacific Biotechnology News* 5: 28-32.
- Gupta S, Kataria M & Gupta, PK (2004) Protective role of extracts of neem seeds in diabetes caused by streptozotocin in rats. *Journal of Ethnopharmacology* 90: 185-189.
- Hara H, Lin YJ, Zhu X, Tai HC, Ezzelarab M, Balamarugan AN, Bottino R, Houser SL, Cooper DK & Ingram LR (2003) Liver function. pp 285-321 in Anderson SC & Cockayne S (eds.) *Clinical chemistry: concepts and applications*. McGraw-Hill, New York
- Husain MK, Anis M & Shahzad A (2007) *In vitro* propagation of Indian Kino (*Pterocarpus marsupium* Roxb.) using Thidiazuron. *In Vitro Cellular & Developmental Biology* 43: 59-64.
- Lowry OH, Oliver H, Rosebrough NJ, Farr AL & Randall RJ (1951) Protein measurement with the folin phenol reagent. *Journal of Biological Chemistry* 193: 265-275.
- Manickam M, Ramanathan M, Jahromi MAF, Chansouria JPN, Ray AB (1997) Antihyperglycemic activity of phenolics from *Pterocarpus marsupium*. *Journal of Natural Products* 60: 609-610.
- Mankani KL, Krishna V, Manjunatha BK, Vidya SM, Singh JSD, Manohara YN, Raheman A & Avinash KR (2005) Evaluation of hepatoprotective activity of stem bark of *Pterocarpus marsupium* Roxb. *Indian Journal of Pharmacology* 37: 165-168.
- Marklund S & Marklund G (1974) Involvement of the superoxide anion radical in the autoxidation of pyrogallol and a convenient assay for superoxide dismutase. *European Journal of Biochemistry* 47: 469-474.
- Maroo J, Vasu VT, Aalinkeel R & Gupta S (2002) Glucose lowering effect of aqueous extract of *Enicostemma littorale* Blume in diabetes: a possible mechanism of action. *Journal of Ethnopharmacology* 81: 317-320.
- Maurya R, Singh R, Mundkinajeddu D, Handa SS, Yadav PP & Mishra PK (2004) Constituents of *Pterocarpus marsupium*: an ayurvedic crude drug. *Phytochemistry* 65: 915-920.
- Montgomery R (1957) Determination of glycogen. *Archives of Biochemistry & Biophysics* 67: 378-386.
- Moron MJ, Depierre JW & Mannivik B (1979) Levels of glutathione, glutathione reductase and glutathione S-transferase activities in rat lung and liver. *Biochimica et Biophysica Acta* 582: 67-68.
- Ohkawa H, Ohishi N & Yagi K (1979) Assay for lipid peroxides in animal tissues by thiobarbituric acid reaction. *Analytical Biochemistry* 95: 351-358.
- Reitman S & Frankel S (1957) A colorimetric method for the determination of serum glutamate oxaloacetate transaminase and glutamate pyruvate transaminase. *American Journal of Clinical Pathology* 28: 56-63.
- Rosen OM, Rubin CS, Coop HM & Smith CJ (1981) Insulin stimulates the phosphorylation of ribosomal protein in a cell free system derived from 3T₃-L adipocytes. *Journal of Biological Chemistry* 256: 3630-3633.
- Sacan OO, Yanardag R, Orak H, Ozgey Y, Yarat A & Tunali T (2006) Effect of Parsley (*Petroselinum crispum*) extract versus glibenclamide on the liver of streptozotocin-induced diabetic rats. *Journal of Ethnopharmacology* 104: 175-181.
- Sallie R, Tredger JM & William R (1999) Drugs and the liver. *Biopharmaceutics & Drug Disposition* 12: 251-259
- Trinder P (1969) Determination of glucose in blood using glucose oxidase with an alternative oxygen acceptor. *Annals of Clinical Biochemistry* 6: 24-27.
- Twaij HA & Al-Badr AA (1988) Hypoglycemic activity of *Artemisia herba alba*. *Journal of Ethnopharmacology* 24: 123-126.
- Varley H (1969) Determination of blood urea by urease nesslerization method. *Practical Clinical Biochemistry* 13: 234.
- Vats V, Grover JK & Rathi SS (2002) Evaluation of antihyperglycemic and hypoglycemic effect of *Trigonella foenum-graecum* Linn, *Ocimum sanctum* Linn and *Pterocarpus marsupium* Linn. in normal and alloxanized diabetic rats. *Journal of Ethnopharmacology* 79: 95-100.
- West JC (2000) Radicals and oxidative stress in diabetes. *Diabetes Medicine* 17: 171-180.
- WHO (1993) WHO Regional Office for the Western Pacific Research Guidelines on evaluating the safety and efficacy of herbal medicines, Manila.

الملخص العربي

التأثير الحامي للكبد لنبات *Pterocarpus marsupium* ضد ضغوط العناصر المؤكسدة راجنيش جيبتا - ر. س. جيبتا

شعبة فسيولوجيا التكاثر - مركز الدراسات المتقدمة - قسم علم الحيوان - جامعة راجاستان - جايبور - الهند
يستخدم نبات *Pterocarpus marsupium* (الفصيلة القرنية) بصورة واسعة في علاج عديد من الخلل المصاحب للعمليات الحيوية داخل الجسم شاملة التسمم الكبدى. أظهرت النتائج أن معالجة فئران التجارب المصابة بمرض السكر بجرعات 100مجم و300مجم لكل 1كجم من وزن الحيوان وذلك بصورة يومية لمدة 21 يوم باستخدام مستخلص النبات المذاب فى الإيثانول قد خفضت نسبة سكر الجلوكوز فى الدم. أوضحت الجرعة العالية قدرة على حماية الجسم من الأعراض البيوكيميائية المصاحبة للتسمم حيث خفضت من الجلوتاثايون وانزيم السوبرأوكسيداز داسموتاس ومؤكسدات الدهون، أيضا حدث تغير في الاتجاه الإيجابى (العادى) فى حجم الكبد ومحتوى البروتين والجليكوجين. ولذا فإن البحث يشير إلى أن مستخلص النبات له تأثير مضاد للسكر وحامى للخلايا الكبدية بالإضافة إلى تأثيره على عوامل الأكسدة بالجسم.